

Original Study

## Pathologic Findings in Ramphastids from 1994 to 2013

Christopher J. Bonar, Michael M. Garner, and Drury R. Reavill

**Abstract:** The family Ramphastidae includes toucans (*Ramphastos* sp), mountain toucans (*Andigena* sp), toucanets (*Aulacorhynchus* sp, *Selenidera* sp), and aracarís (*Pteroglossus* sp). These birds are endemic to Central and South America and are popular birds for zoological parks and as companion animals. This retrospective study summarizes the histologic findings of 273 toucans, 24 mountain toucans, 240 aracarís, and 64 toucanets (601 total specimens) submitted to 4 diagnostic laboratories from 1994 through January 2013. Infectious diseases were most common (53.1%, 319/601), followed by nutrition-based deposition disorders (36.4%, 219/601) and cardiovascular disease (10.3%, 62/601). Among infectious diseases, bacterial diseases were most common (57%, 182/319, including 45 cases of mycobacteriosis). Mycotic diseases (14.1%, 45/319) included ventricular candidiasis (73.3%, 33/45), aspergillosis (13.3%, 6/45), and undetermined fungus (13.3%, 6/45). Viral infection was limited to 3 cases with 2 cutaneous poxvirus cases and 1 West Nile virus case. Parasitic infections were found in 93 cases, including nematodiasis (64.5%, 60/93, predominantly *Capillaria* sp). Intestinal trematodiasis, muscle cysts of *Sarcocystis* sp, hepatic hemoprotozoan macroschizonts, biliary and intestinal trematodiasis, amoebiasis, and cestodiasis represented <5% of cases. Parasitic infections were undetermined in 6.4% (6/93) of cases. Deposition cases included iron storage disease (77.7%, 230/296), gout (14.9%, 44/296), and amyloidosis (7.4%, 22/296). Cardiovascular disease (62 cases) included atherosclerosis (48.4%, 30/62) and degenerative cardiac disease (4.8%, 3/62); 3 cases of dilated cardiomyopathy were found in young aracarís. The results of this study indicate that mortalities could be diminished in < 1 year old birds by improved prevention and treatment of enteric infections and that, in > 1 year old birds, prevention and treatment of *Capillaria* sp and hemochromatosis may also substantially reduce mortality.

**Key words:** hemochromatosis, pathology, avian, ramphastid, toucan, toucanet, aracarí, *Capillaria*

### INTRODUCTION

Toucans (*Ramphastos* sp), mountain toucans (*Andigena* sp), toucanets (*Aulacorhynchus* sp, *Selenidera* sp), and aracarís (*Pteroglossus* sp) are in the order Piciformes and have long been popular in zoological parks, aviaries, and aquariums. They are some of the most well-known and readily recognizable birds from South America. Prior to the Wild Bird Conservation Act of 1992, they were commonly imported into the United States for the pet trade and for zoological parks and aviaries. After 1992, importation became less frequent, and captive propagation of these species has been successful.

These birds can be long-lived with proper nutrition, husbandry, and medical care; however, relatively few institutions have had long-term sustainable breeding populations. This retrospective study reviewed the histopathologic lesions identified in toucans, mountain toucans, toucanets, and aracarís from multiple institutions.

### MATERIALS AND METHODS

Toucans, mountain toucans, toucanets, and aracarís submitted for histologic examination to 4 diagnostic pathology services (Northwest ZooPath, Monroe, WA, USA; Zoo/Exotic Pathology Service, West Sacramento, CA, USA; Texas Veterinary Medical Diagnostic Laboratory, College Station, TX, USA; Noah's Path, Elche, Spain) were examined for histopathologic findings. In almost all cases, necropsy was performed by the attending clinician at the submitting institution, and representative sections of lesions and major organs were fixed and submitted in 10% neutral buffered formalin. Tissues were

---

From the Dallas World Aquarium, 1801 N. Griffin Street, Dallas, TX 75202, USA (Bonar); the Pittsburgh Zoo and Aquarium, 1 Wild Place, Pittsburgh PA 15206, USA (Bonar); Northwest ZooPath, 654 W Main Street, Monroe, WA 98272, USA (Garner); and Zoo/Exotic Pathology Service, 2025 KOVR Drive, West Sacramento, CA 95605, USA (Reavill, deceased).

Corresponding Author: Christopher J. Bonar, cbonar@pittsburghzoo.org

processed routinely, embedded in paraffin, sectioned at 4–5  $\mu\text{m}$ , mounted on frosted slides, and stained with hematoxylin and eosin. Select tissues were also stained with Ziehl-Neelson and/or Fite acid-fast stains, Brown and Brenn Gram's stain, Gomori or Grocott methenamine silver stains, and/or Fontana-Masson stain. Bones were first decalcified by immersion in 5% formic acid, 0.1% ethylenediaminetetraacetate (Rapid-Cal, Biesecker Bio Chemical, Mt. Vernon, WA, USA), or a 0.5 M EDTA solution made in-house from component reagents (Fisher Scientific, Pittsburgh, PA, USA) for 24–48 hours. Histologic sections were always examined by diplomates of the American College of Veterinary Pathologists using light microscopy. Histologic diagnoses, both primary cause of death and comorbidities, were numerically coded, and cases were retrieved and sorted by computer-assisted code searches. Findings were categorized by etiologic agent. Ages of the birds were obtained, whenever possible, and birds were categorized as >1 year old or <1 year old. Limitations in a study such as this include that there were multiple veterinarians submitting samples from several different institutions over many years, so not every case had all the same organs sampled in the same way. Therefore, there is some variability in the completeness of the set of tissues from each case. In addition, culture results, radiographs, and clinical findings were not available for review in most cases.

## RESULTS

Tissue samples from 601 birds, including 273 toucans (128 male, 110 female, and 35 of undetermined sex), 24 mountain toucans (9 male, 4 female, and 11 of undetermined sex), 240 aracarids (91 male, 74 female, and 75 of undetermined sex), and 64 toucanets (29 male, 27 female, and 8 of undetermined sex), were examined from 46 institutions and several private individuals. For the toucans, the 5 most common species were the toco toucan (*Ramphastos toco*; 42.8%, 117/273), keel-billed toucan (*Ramphastos sulfuratus*; 18.3%, 50/273), Swainson toucan (*Ramphastos swainsoni*; 10.6%, 29/273), white-throated toucan (*Ramphastos tucanus*; 7.7%, 21/273), and channel-billed toucan (*Ramphastos vitellinus*; 5.1%, 14/273); the remainder of cases were unspecified. For the toucanets, the 4 most common species were the spot-billed toucanet (*Selenidera maculirostris*; 23.4%, 15/64), Guianan toucanet (*Selenidera piperivora*; 10.9%, 7/64), groove-billed toucanet (*Aulacorhynchus sulcatus*; 7.8%, 5/64), and crimson-rumped toucanet (*Aulacorhynchus haematopygus*; 7.8%, 5/64); others were unspecified or represented by only 1 or 2 specimens. Of the aracarids, the 5 most common species were the black-necked aracari (*Pteroglossus aracari*; 17.1%, 41/240), green

**Table 1.** Mean, median, and age ranges of ramphastids categorized by origin (wild caught, captive hatched, and origin unknown) submitted for pathological evaluation.

Type of bird (origin)	N	Mean age, y	Median age, y	Range, y
Toucan (wc)	69	8.35	8.51	1.18–19.78
Toucan (ch)	82	5.39	3.95	0.003–16.46
Toucan (uo)	43	7.59	7.82	0.5–19.59
Mtn. toucan (wc)	1	N/A	N/A	N/A
Mtn. toucan (ch)	12	1.81	0.04	0.003–10.24
Mtn. toucan (uo)	5	5.22	3.51	2.77–13.42
Aracari (wc)	17	6.78	7.07	2.32–18.66
Aracari (ch)	122	2.93	0.81	0.003–24.03
Aracari (uo)	29	5.12	4.04	0.7–13.25
Toucanet (wc)	13	6.34	6.78	1.04–12.4
Toucanet (ch)	38	3.71	2.04	0.003–16.76
Toucanet (uo)	13	6.9	7.07	0.55–12.26

Abbreviations: wc, wild caught; ch, captive hatched; uo, unknown origin.

aracari (*Pteroglossus viridis*; 11.2%, 27/240), curl-crested aracari (*Pteroglossus beauharnaisii*; 7.9%, 19/240), collared aracari (*Pteroglossus torquatus*; 6.2%, 15/240), and ivory-billed aracari (*Pteroglossus azara*; 6.2%, 15/240); other species were less numerous or unspecified. Of these birds, 389 records included bird origin with 98 (25.2%) specimens known to be wild caught and 291 (74.8%) captive bred; the remaining cases were of unreported provenance.

Mean, median, and age ranges of the specimens at death can be found in Table 1. For each group of ramphastids (toucans, aracarids, and toucanets), the captive-hatched specimens outnumbered the wild-caught group, but there were substantial numbers of specimens of all types that were of unreported provenance. Mean and median ages of the captive-hatched specimens were lower for each group than that of wild-hatched specimens. Of those for which sex was specified, males and females were submitted in approximately equal numbers, but many specimens were of unreported or undetermined sex. In most cases, only gross necropsy findings and histopathologic findings were available; culture results and radiographs were usually not available. Etiologic diagnoses are summarized in Table 2.

## Infectious diseases

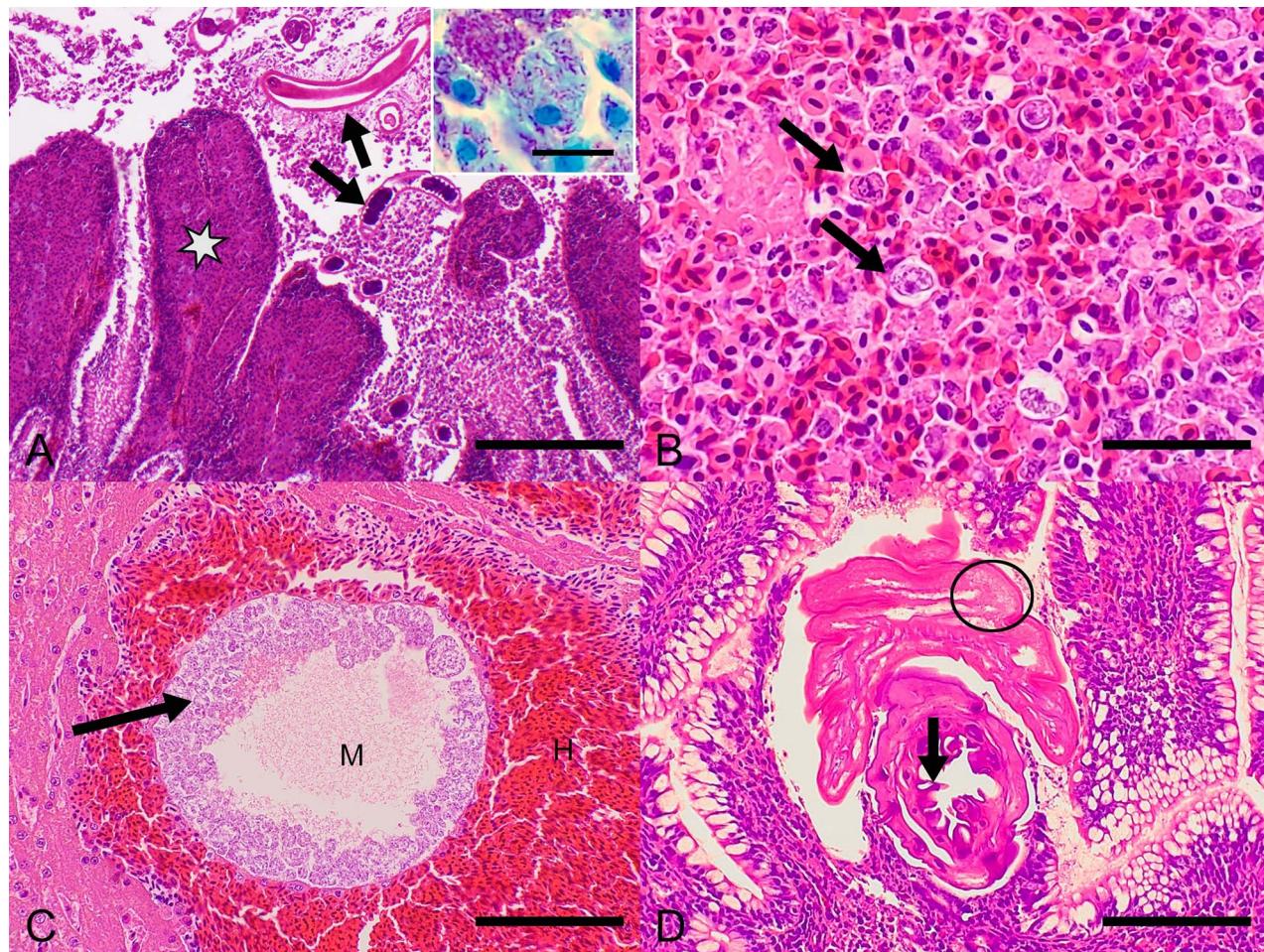
**Parasitic infections:** Ninety-three cases of parasitic infections were identified using gross and histologic lesion morphology (53 toucans, 5 mountain toucans, 10 toucanets, and 25 aracarids). The most frequently affected tissues were in the gastrointestinal tract, although intravascular and cerebral nematodes were observed in several cases. There were 60 cases of

**Table 2.** Etiologic diagnoses based on pathology findings for ramphastids (n = 601).

Findings	Toucans	Mountain toucans	Toucanet	Aracaris	n
	273	24	64	240	601
Bacterial					
Bacterial (nonmycobacterial)	48	5	16	68	137
Mycobacterial	30	1	7	7	45
<i>Total</i>	78	6	23	75	182
Fungal					
<i>Candida</i>	6	5	1	21	33
<i>Aspergillus</i>	3	0	1	2	6
Unidentified fungus	1	0	1	4	6
<i>Total</i>	10	5	3	27	45
Parasitic					
Nematodes	36	2	8	14	60
Trematodes	4	0	0	2	6
Cestodes	2	0	0	1	3
Unspecified	2	2	2	0	6
Acanthocephalids	0	1	0	5	6
Amoebozoa	4	0	0	0	4
Unspecified flagellates	2	0	0	0	2
<i>Sarcocystis</i> sp	3	0	0	3	6
<i>Total</i>	53	5	10	25	93
Deposition					
Hemosiderosis	56	2	5	57	120
Hemochromatosis	83	0	2	25	110
Urates	27	1	5	11	44
Amyloid	11	1	2	8	22
<i>Total</i>	177	4	14	101	296
Miscellaneous diseases					
Cardiovascular disease					
Arteriosclerosis	3	0	1	0	4
Atherosclerosis	21	0	6	3	30
Epicarditis	0	1	0	2	3
Myocarditis	3	2	3	4	12
Fibrosis	5	0	0	2	7
Myopathy	0	0	0	3	3
Vasculitis	1	2	0	0	3
<i>Total</i>	33	5	10	14	62
Degenerative joint disease	0	0	1	0	1
Neoplasia	6	0	5	2	13
Smoke inhalation	0	0	0	5	5
Trauma	13	2	4	22	41

nematode infections (30 *Capillaria* spp, 30 unspecified) (Fig. 1A). In some cases, bacterial infection (eg, mycobacteriosis) was a concomitant finding (Fig. 1A, inset). Eight of these cases were described alongside a diagnosis of parasitic enteritis and were a significant contributing factor to the cause of death, whereas the remainder of cases were considered incidental. The 4 cases of amoebiosis were in toucans (*Ramphastos* sp) with lesions of granulomatous splenitis and hepatitis (Fig. 1B). In most cases, the parasites were not further characterized. Sarcocysts were observed in skeletal muscle in 3 toucans

and were considered incidental findings; sporozoan parasites (immature stages of malarial parasites) were found in the livers of 2 toucans with hepatitis (Fig. 1C). There were 6 cases of acanthocephalid infections (5 in pale-mandibled aracaris [*Pteroglossus erythropygius*] and 1 in a plate-billed mountain toucan [*Andigena laminirostris*]), and all appeared to be clinically significant (Fig. 1D). There were 6 cases of trematode infections and 3 cases of cestodiasis. Intestinal cestodes were the only postmortem finding in 1 toucan and 1 aracari, but the 1 toucanet that died of inanition was parasitized by

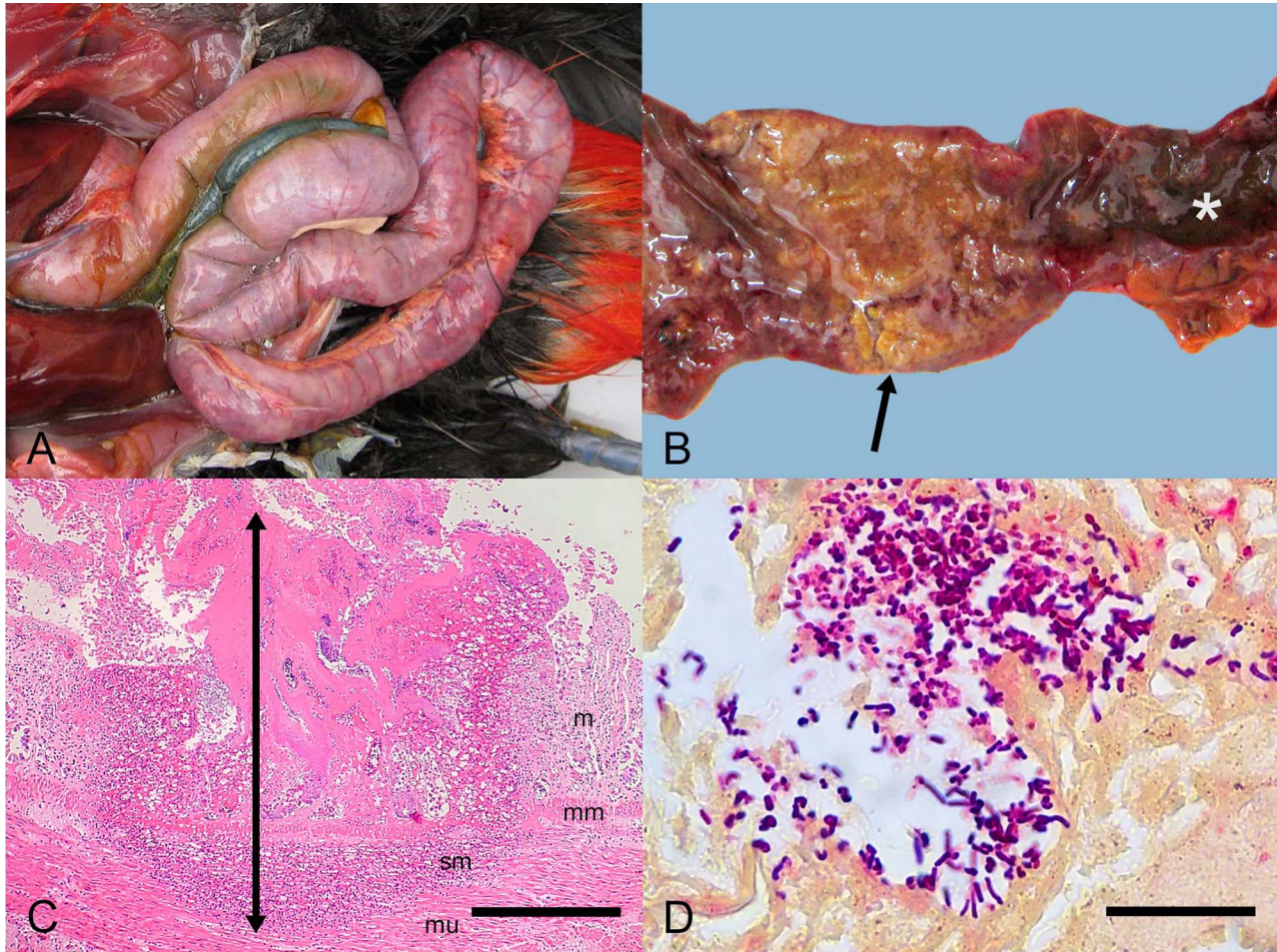


**Figure 1.** Various parasites and mycobacteriosis cases in ramphastids. (A) Toco toucan (*Ramphastos toco*) with small intestinal *Capillaria* (arrow) and histiocytic enteritis (\*) attributed to mycobacteriosis. Hematoxylin and eosin, Bar = 400  $\mu$ m. Inset = intracellular acid-fast bacteria. Fites acid-fast stain, Bar = 30  $\mu$ m. (B) Toco toucan spleen with histiocytic inflammation and necrosis associated with numerous amoeba (arrows). Hematoxylin and eosin, Bar = 60  $\mu$ m. (C) Liver from a green aracari (*Pteroglossus viridis*) has a megaloschizont (M) of a hemoparasite that contains numerous meronts (arrow). Note extensive hemorrhage (H) around the megaloschizont. Hematoxylin and eosin, Bar = 200  $\mu$ m. (D) Small intestine of a pale mandibled aracari (*Pteroglossus erythropygius*) with an acanthocephalan embedded in the mucosa. Note the armed (hooked) proboscis (arrow) and bilayered body wall (circle) characteristic of these parasites. Hematoxylin and eosin, Bar = 450  $\mu$ m.

cestodes, nematodes, and sarcocysts. There was 1 case of *Cryptosporidium* sp, with cryptosporidial enteritis the only postmortem finding in that case.

**Bacterial infections:** A total of 182 cases of bacterial infection were observed (78 toucans, 6 mountain toucans, 23 toucanets, and 75 aracaris). Based on lesion morphology and special stains, 45 cases were of *Mycobacterium* sp origin, and 137 were considered "other bacteria." For the 137 nonmycobacterial cases, the distributions of the lesions were 56.9% (78/137) gastrointestinal tract, 32.8% (45/137) septicemia, 18.9% (26/137) liver, 10.2% (14/137) generalized coelomic cavity, 5.8% (8/137) kidney, 5.8% (8/137) yolk sac, 5.1% (7/137) spleen, and 5.1% (7/137) heart; many birds had more than 1 lesion. Bacterial gastroenteritis was the most

common finding in <1 year of age captive-bred ramphastids and was associated with 30.4% (31/102) of deaths in these birds. Although culture results were not available for many cases, in 1 series of deaths in birds < 1 year old, *Salmonella* sp was consistently isolated by culture and polymerase chain reaction testing of the gastric mucosa. Clostridial enteritis was also frequently observed (Fig. 2 A-D). Two cases of *Yersinia* sp were also confirmed by culture in 1 toco-toucan and 1 channel-billed toucan, both from the same institution. Forty-five cases of mycobacteriosis were identified (Fig 1A) based on lesion morphology and acid-fast staining. Median age at death for mycobacteriosis cases was 7.9 years. Lesions were found in the liver (53.3%, 24/45), gastrointestinal tract (42.2%, 19/45), spleen (33.3%, 15/45),



**Figure 2.** Clostridial enteritis in a toco toucan (*Ramphastos toco*). (A) Note dilatation of the intestine. (B) Note pseudomembrane formation (arrow) and melena (\*) on mucosal surfaces. (C) Note full-thickness mucosal ulceration, necrosis, and pseudomembrane formation with extension of this process through the muscularis mucosa and into the submucosa and muscularis tunic (double arrow). m = mucosa, mm = muscularis mucosa, sm = submucosa. Hematoxylin and eosin, bar = 1 mm. (D) Higher magnification of C showing large numbers of Gram-positive bacteria along necrotic surfaces of the mucosa. Brown and Brenn, bar = 20  $\mu$ m.

lungs (31.1%, 14/45), coelomic membranes and fat (28.9%, 13/15), kidneys (26.7%, 12/45), adrenal glands (11.1%, 5/45), pancreas (8.9%, 4/45), heart (6.7%, 3/45), and ovary (2.2%, 1/45 cases).

**Fungal infections:** Fungal infections were identified in 45 cases (10 toucans, 5 mountain toucans, 3 toucanets, and 27 aracarís); 33 (73%) were associated with *Candida* spp infections in the ventriculus and proventriculus, and 6 (13%) were *Aspergillus* spp infections associated with the respiratory tract and serosal surfaces of the viscera. *Candida* infections were encountered 10 times more frequently in birds <1 year old than birds >1 year old. The remaining 6 cases (14%) were attributed to unspecified fungal infections.

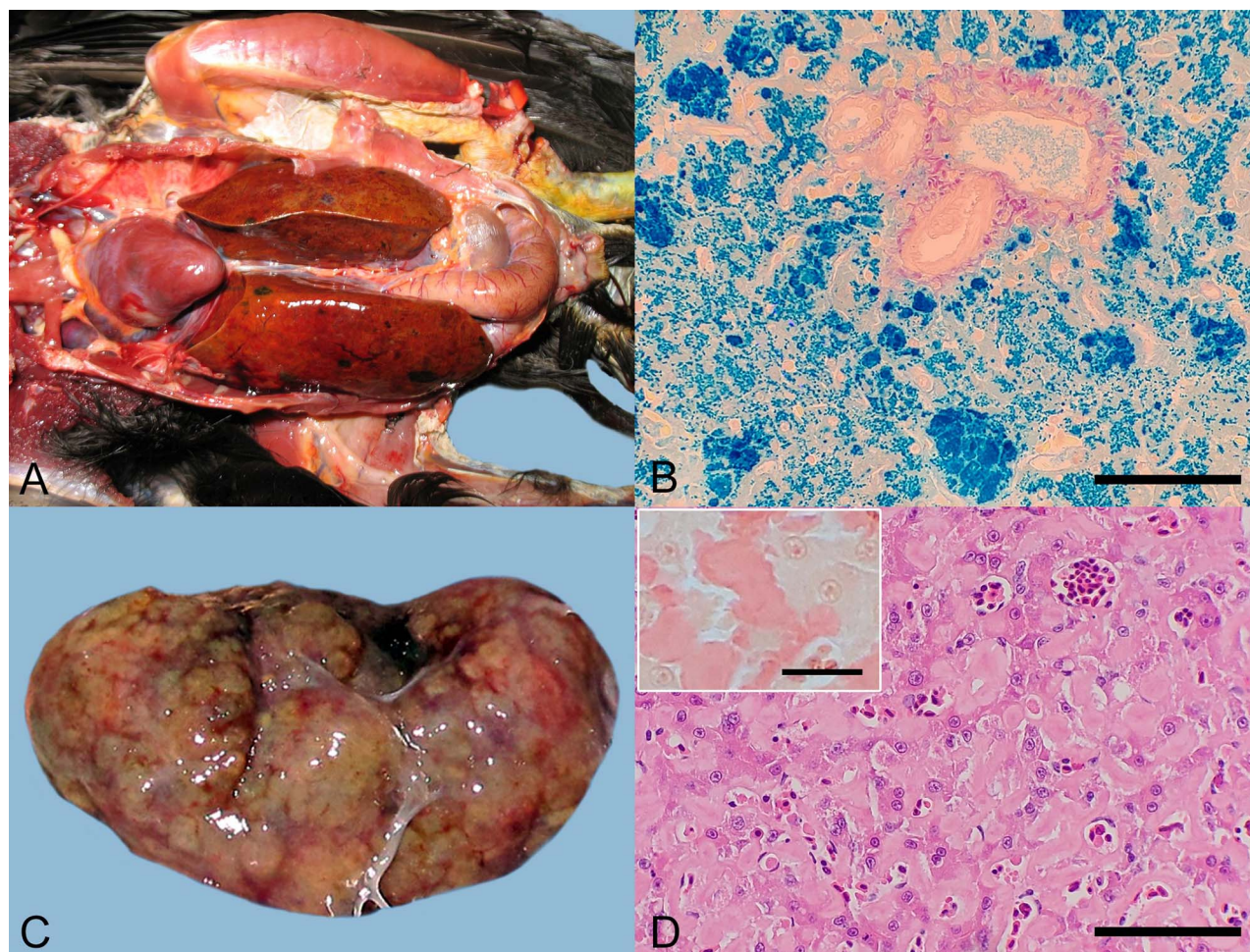
**Viral infections:** There were only 3 cases of confirmed viral disease (2 toucans and 1 mountain toucan). West Nile virus was diagnosed in a plate-billed mountain toucan (*Andigena laminirostris*), and

cutaneous poxvirus was diagnosed in 2 toucans (*Ramphastos* sp.).

#### Noninfectious diseases

**Trauma:** There were 41 cases of trauma (13 toucans, 2 mountain toucans, 4 toucanets, and 22 aracarís) diagnosed based on case history and gross and/or histologic evidence of tissue damage or hemorrhage. Median age at death for trauma cases was 6.7 years. There were 7 (17.1%) cases of head trauma, 1 (2.4%) leg fracture, and 1 (2.4%) spinal fracture reported. In 8 (19.5%) cases, intraspecific aggression was reported, and in 1 (2/4%) case, interspecific aggression was reported. In the remaining 23 (56.1%) cases, no specific details were provided.

**Tracheitis:** There was 1 case of proliferative tracheitis in a juvenile plate-billed mountain toucan after intubation for surgery.



**Figure 3.** Deposition disorders in ramphastids. (A) Keel-billed toucan (*Ramphastos sulfuratus*) with iron storage disease (hemochromatosis). Note bilateral hepatic enlargement and amber discoloration of the hepatic parenchyma. (B) Histologic image of iron storage disease in the liver. Iron deposition is marked in the hepatocytes and associated with iron laden Kupffer cell microgranulomas. Prussian blue, bar = 200  $\mu$ m. (C) Saffron toucanet (*Pteroglossus bailloni*) spleen with amyloidosis. Note coalescing tan nodular foci throughout the spleen. (D) Toucan (*Ramphastos* sp) liver with amyloidosis. Note extracellular amorphous eosinophilic material that expands the space of Disse and is associated with disruption and compression of hepatic cords. Hematoxylin and eosin, bar = 160  $\mu$ m. Inset: higher magnification of amyloid deposits in the space of Disse, Congo red, bar = 80  $\mu$ m.

**Neoplasia:** There were 19 cases of neoplasia reported in 11 toucans, 1 mountain toucan, 5 aracarís, and 2 toucanets. The median age at death was 10.9 years with a range of 0.59 to 18.8 years. Three (15.8%) neoplasms were of pancreatic origin (2 exocrine adenocarcinomas, 1 beta islet cell carcinoma), and 6 (31.6%) were renal tubular adenomas or adenocarcinomas. There were 3 (15.8%) hepatocellular carcinomas, 1 in a toucanet and 2 in toucans. Other neoplasms (bile duct carcinoma, lymphosarcoma, air sac adenocarcinoma, hemangiosarcoma) were represented by 1 or 2 cases each. The 1 (5.2%) juvenile bird, a green aracarí, was a case of lymphosarcoma.

**Deposition disorders:** Deposition disorders were commonly identified in these birds (160 toucans, 3

mountain toucans, 11 toucanets, and 45 aracarís). Iron deposition was most common with 181 cases presenting as either hemosiderosis (120 cases; iron deposition present but no cellular or architectural changes in tissue), hemochromatosis (110 cases; iron deposition accompanied with pathology: hepatocellular anisokaryosis or anisocytosis, cholestasis, biliary hyperplasia, hepatic fibrosis, or necrosis), or both types of deposition disease in different organs (49 cases) (Fig 3 A-D). In the cases of hemosiderosis for which distribution could be determined from the record, disease was identified in the liver (73.7%, 56/76), spleen (11.8%, 9/76), kidney (9.2%, 7/76), gastrointestinal tract (2.6%, 2/76), and other organs (2.6%, 2/76). Median age at death for hemosiderosis cases was 7.17 years. In cases of hepatic

hemochromatosis for which additional iron distribution could be distinguished by organ system, disease was found in the kidney (15.8%, 13/82), spleen (8.5%, 7/82), and gastrointestinal tract (4.9%, 4/82). Other organ systems were only represented by 1 or 2 cases. Median age at death for hemochromatosis cases was 7.95 years.

*Uric acid deposition:* For the cases of uric acid deposition for which deposition site could be determined, urate accumulation was found in the kidneys (86.5%, 32/37), joints (10.8%, 4/37), heart (5.4%, 2/37), and generalized visceral organs (10.8%, 4/37). In some cases, multiple systems were affected.

*Amyloid deposition:* For cases of amyloid deposition in which deposition patterns were reported, the affected organ systems included the liver (56.5%, 13/23), kidney (39.1%, 9/23), gastrointestinal tract (39.1%, 9/23), spleen (21.7%, 5/23), heart (13%, 3/23), and pancreas (8.7%, 2/23). In some cases, multiple systems were affected. Birds with amyloid deposition had a median longevity of 8.0 years.

*Atherosclerosis:* Atherosclerosis was diagnosed in 30 cases (21 toucans, 6 toucanets, and 3 aracarís). In most reports, it was just listed as atherosclerosis; however, in 15 cases, the tissue was reported: cardiac vessel (53.3%, 8/15), "great vessel" (40%, 6/15), and "multiple organs" (6.7%, 1/15). In most cases, the severity of the atherosclerosis was not reported; however, when reported, the severity ranged from a mild classification to a severe enough classification to be suspected of being the cause of death in 1 case. Arteriosclerosis was observed in 4 cases (3 toucans and 1 toucanet).

*Endocrine diseases:* Three clinical diabetes cases were reported in toco toucans; however, histologic pancreatic fibrosis was only observed in 1 of these cases. There was also 1 case of thyroiditis in a green aracarí.

## DISCUSSION

Infectious diseases were the most common cause of death in this cohort of ramphastid birds. Bacterial infections are a substantial problem in ramphastids and, in the present study, were the most common infectious disease. Moreover, bacterial gastroenteritis was especially common in juvenile, captive-bred ramphastids. In previous reports, Gram-negative aerobic bacteria were noted to be the most likely enteric pathogens, and *Salmonella* sp, *E coli*, *Providencia* sp, and *Yersinia* sp have all been implicated.<sup>1-5</sup> Necropsy findings included hepatomegaly, splenomegaly, small pale tan foci in the air sacs, acute catarrhal enteritis, and (sometimes) pericarditis. Hepatic lesions included focal regions of necrosis with peri-biliary inflammation and varying degrees of

pigment deposition.<sup>5,6</sup> Anaerobic bacteria, such as *Clostridium* sp and *Bacteroides* sp, are also reported to cause severe, necrotizing enteritis with nodular and caseous granuloma formation and hepatic granulomas<sup>1,2</sup> (Fig 3 A-D). Yersiniosis has been reported in captive toucans, causing severe intestinal lesions and death,<sup>4</sup> and was also found in the present study. However, all the cases came from 1 colony, and therefore, whereas it is highly pathogenic, *Yersinia* infections do not appear to be widespread among zoological parks.

Mycobacteriosis was a frequent finding in the present study (Fig 1A), and these infections have been previously reported in ramphastids.<sup>1</sup> Of the *Mycobacterium* cases diagnosed in this study, most were single cases, and only 2 institutions had more than 1 case. One institution had 3 cases and another 2 cases, but the cases were spaced 3 and 5 years apart and 7 years apart, respectively. Whereas isolation and identification of the *Mycobacterium* spp were not available for any of these cases, the distribution of cases among institutions and over time is consistent with findings in other studies. None of these cases was from an outbreak of mycobacterial disease, which makes sense in view of the feeding habits of these birds because they are usually fed fruit and prepared pellets in food bowls elevated off the ground. This strategy reduces the likelihood that food is contaminated with avian feces or soil.

Nematodes were the most frequently found parasite, and *Capillaria* spp were 1 of the most common and serious diseases encountered in this survey (Fig 1A). It has been reported to be the most important infectious disease of toucans in Brazil, causing loss of bodily fluids, hyporexia, lethargy, and brown to bloody diarrhea with anemia.<sup>2,3</sup> *Capillaria* spp have also been reported in 4 species of toucans in a single report in which 17 of 71 cases had helminthiasis of some kind.<sup>5</sup> *Capillaria* spp are common in other avian species too and become infective in 2 weeks and remain so for many months; with few exceptions, they have a direct life cycle.<sup>7</sup> *Capillaria* spp have been reported to be resistant to numerous anthelmintics; however, levamisole, methyridine, and fenbendazole have been found to be effective.<sup>2,8-10</sup> Unspecified nematodiasis was documented in 1 report in 8 species of toucans with mucosal granulomas.<sup>5</sup>

Trematodes, cestodes, and acanthocephalids were found less frequently (Fig 1D). Trematodes were found in the kidneys of an Ariel toucan (*Ramphastos ariel*), which was considered an incidental finding in a previous study.<sup>5</sup> Successful treatment of trematodes has been reported previously in a red-billed toucan (*Ramphastos tucanus*).<sup>5,10</sup> Similarly, acanthocephalids were also

occasionally encountered in this study, and all cases appeared to substantially contribute to death. Previously, an infection reported in a Cuvier toucan (*Ramphastos cuvieri*)<sup>5</sup> was believed to be an incidental finding; however, in large numbers, acanthocephalids have been shown to be serious pathogens in other species.<sup>11</sup> Filarial tenosynovitis has been reported in a channel-billed toucan with swollen joints;<sup>12</sup> however, no similar cases were found in the present study.

*Eimeria*, *Plasmodium*, *Sarcocystis*, and *Giardia* have all been reported in wild toucans in Brazil.<sup>2</sup> *Sarcocystis* sp has also been described in a keel-billed toucan in human care.<sup>13</sup> *Sarcocystis* was observed in the skeletal muscles in 3 toucans in the current cohort. Sporozoan parasites (immature stages of malarial parasites) were found in the livers of 2 toucans with hepatitis (Fig 1C). Unfortunately, further identification of these parasites to the genus and species level was not possible. Amoebas were found in 4 birds, including 3 toco toucans and 1 keel-billed toucan (Fig 1B). The amoebas from the keel-billed toucan were cultured and determined to be *Acanthamoeba* genotype T4 by molecular methods.<sup>14</sup> This individual was a confiscated, illegally imported bird and is, therefore, believed to have been wild hatched. Of the 3 toco toucans with amoebiasis, 2 were wild hatched, and 1 additional bird was of undetermined origin. It is, therefore, possible that most or all these amoebic infections were acquired in nature. *Cryptosporidium* was found in 1 case with enteritis. Although *Cryptosporidium* can cause both enteric and respiratory infection in birds,<sup>15</sup> it was only found in this single case of enteric infection in the ramphastids studied here.

Fungal infections have been previously reported in ramphastids, including yeasts such as *Candida* spp and molds such as *Aspergillus* spp.<sup>1-3,16</sup> *Candida* was reported to have caused severe necrotizing esophagitis in 1 toco toucan, and *Candida* and *Aspergillus* have been observed in debilitated birds and chicks.<sup>2</sup> However, in the present study, fungal infections were relatively uncommon, and most were *Candida* spp enteritis cases in birds < 1 year old. The observation that *Candida* gastritis and enteritis was encountered 10 times as commonly in birds < 1 year old suggests that this age cohort is more susceptible to infection than adults. In these cases, the *Candida* infections were usually severe and either the cause of or substantially contributory to death. *Aspergillus* appears to be uncommon in ramphastidae compared with its incidence in more susceptible species, such as spheniciformes, falconiformes, galliformes, and anseriformes.

Viral infections were relatively rare in this cohort, and there were only 3 confirmed viral cases: 2 cases

of poxvirus in toucans (*Ramphastos* sp) and 1 case of West Nile virus in a subadult plate-billed mountain toucan. All these cases were housed outdoors and would, therefore, be expected to have exposure to insect vectors. Herpesvirus has been previously reported in 1 species of toucan; however, no cases were seen in the present study.<sup>17</sup>

Deposition diseases were the most common noninfectious disorder observed and the most common problem after infectious disease. Hemochromatosis was commonly found in this study as were the lesser lesions of hemosiderosis (Fig 3A and B). Hemochromatosis has previously been reported as a common cause of mortality in toucans.<sup>1-4,18,19</sup> In a single report, at least 13 different species were reported to suffer from hemochromatosis, and the 3 most commonly affected species (the toco toucan, the keel-billed toucan, and white throated toucan) were also the most commonly kept species in captivity.<sup>4</sup> Hemochromatosis has also recently been reported in a channel-billed toucan in a zoological park in Brazil.<sup>20</sup> Clinical signs can include dyspnea, anorexia, and poor feathers although peracute death with no premonitory signs is also common.<sup>2</sup> Necropsy findings with hemochromatosis have been reported to include hepatomegaly, fibrosis, fibrin deposition, and ascites.<sup>2</sup> The present study confirmed these findings.

The etiopathogenesis of hemochromatosis is complex, involving the interaction of iron content of the diet, possible iron-binding compounds in the food and the water, species-specific peculiarities of absorption and excretion, and possibly even concomitant parasitism.<sup>4,19-23</sup> The effective use of tea in the diet to mitigate availability of dietary iron in another iron-sensitive bird, the common starling (*Sturnus vulgaris*), has been documented.<sup>24</sup> Therefore, diets formulated to be low in iron with limited citrus and ascorbic acid (which enhances iron uptake) and that include tannins (such as from tea) or other dietary phytochemicals in the food and water may substantially mitigate dietary iron overload in these species. Hemosiderosis, or iron deposition without associated inflammation and organ damage, was also common. Whether these cases would have eventually progressed to hemochromatosis is unknown. In 1 published case, it was speculated that iron deposition may have predisposed to *Klebsiella* septicemia, but similar correlations were not observed in cases in this study.<sup>25</sup>

Uric acid deposition is a well-recognized problem in avian medicine and is usually the result of dehydration, renal failure, or dietary imbalances.<sup>25</sup> Renal tubular gout was the most common manifestation of uric acid deposition in this study, accounting for approximately

half of all kidney problems. These results suggest that dehydration commonly played a role in the pathogenesis of the lesions.

Amyloidosis was an occasional finding in this cohort (Fig 2C and D). Whereas the exact mechanism that triggers amyloidosis is unknown, chronic inflammation appears to be able to trigger amyloid production and deposition, and certain species are known to be more prone to amyloid deposition than others. Amyloidosis is more commonly reported in waterfowl; many but not all these cases are reported to have concurrent mycobacteriosis or are associated with crowding and/or social stress.<sup>26</sup> It has also been reported occasionally in other species of birds, including Lady Gouldian finches (*Erythrura gouldiae*), flamingos, raptors, hooded mergansers (*Lophodytes cucullatus*), and Japanese quail (*Coturnix japonica*).<sup>27–30</sup>

Avian atherosclerosis is well described in other species, including penguins, cranes, storks, herons, psittacine birds, and gallinaceous birds.<sup>31</sup> Whether or not there might be a dietary or husbandry component to this disorder in ramphastids could not be determined from this data set because dietary information was not available. However, based on these results, there is merit in further evaluating the potential association between diet and atherosclerosis for these species.

Trauma has been previously reported to cause as much as 35% of mortalities in captive ramphastids.<sup>5</sup> Although our study includes a substantial number of trauma cases, trauma may account for an even higher proportion of mortalities in captive populations because clinicians may not submit tissues for histopathology from obvious trauma cases without gross evidence of concomitant disease processes. Incidental findings concomitant with the trauma in the current study included aspiration of water, iron storage disease, cachexia, ventricular nematodiasis, and physiologic shock.

Proliferative tracheitis has been reported in multiple birds of different species after tracheal intubation for anesthesia.<sup>32–34</sup> This is an occasional postintubation problem in birds, and the precise etiopathogenesis is not well understood; however, it is clearly associated with a proliferative response due to irritation or ischemic necrosis associated with endotracheal intubation. There was only a single case in this cohort in a plate-billed mountain toucan following endotracheal intubation with an uncuffed tube.

Neoplasia was an uncommon finding in this cohort, and all but 1 case were in older adult birds. In the present study, there were not enough cases of any 1 neoplasm found to draw any definitive conclusions about species-specific predisposition or other risk

factors for development of neoplasia. Renal neoplasia has been previously reported in 1 channel-billed toucan, but appears to be rarely reported in the literature.<sup>35</sup>

Enteric infections with bacteria (eg, *Salmonella* spp) and yeast (eg, *Candida* spp) are serious causes of mortality in ramphastids, especially birds < 1 year old. Establishing protocols focused on biosecurity and preventive strategies against these infections could significantly improve the long-term sustainability of these species in human care. *Capillaria* sp infections are also a significant cause of morbidity and mortality for adult ramphastids, and research on improved pharmacologic methods for treating *Capillaria* sp could have significant impact in improving the medical care of these species.

Despite long-standing awareness of the problem of hemochromatosis in these species, as well as the availability of low-iron prepared diets, hemochromatosis was found in a substantial number of ramphastids in this study. A more thorough and systematic evaluation of the various diets being offered to further reduce the risk of iron exposure may significantly improve the longevity of these species in human care. Investigations into the effects of dietary tannins and phytochemicals to bind and thereby reduce the bioavailability of iron in ramphastids are warranted. Renal tubular gout was a common renal ailment, and therefore, efforts at maintaining adequate hydration in ramphastids, especially those with other medical conditions, may help to reduce the risk of renal disease in these birds.

*Acknowledgments:* We thank the late Christie Buie, NorthWest ZooPath, for her diligent help with the images and database searches; Carles Juan-Salles DVM, DACVP, and Mireia Mainez, DVM, for the inclusion of their cases; Daryl Richardson, Director, Dallas World Aquarium, for his support and encouragement of this project; and Cydney Capelle for providing a review of the manuscript.

## REFERENCES

1. Cubas Z. Piciformes. In: Fowler ME, Cubas Z, eds. *Biology, Medicine, and Surgery of South American Wild Animals*. Philadelphia, PA: Saunders; 2001:180–199.
2. Cubas Z. Piciformes (woodpeckers, barbets, puffbirds, jacamars, and toucans). In: Fowler ME, ed. *Zoo and Wild Animal Medicine*, vol 5. Philadelphia, PA: Saunders; 2003:180–199.
3. Sykes J. Piciformes (honeyguides, barbets, woodpeckers, toucans). In: Miller RE, Fowler M, eds. *Fowler's Zoo and Wild Animal Medicine*, vol 8. Philadelphia, PA: Saunders; 2014:230–238.
4. Worrell, A. Further investigations in ramphastids concerning hemochromatosis. *Proc Ann Conf Am Assoc Avian Vet*. 1993:98–107.

5. Griner L. Birds: order Piciformes. In: *Pathology of Zoo Animals*. San Diego, CA: Zoological Society of San Diego; 1983:246–250.
6. Cubas Z. Diseases of free-ranging birds in South America. In: Fowler ME, Miller RE, eds. *Zoo and Wild Animal Medicine*, vol 3. St. Louis, MO: Saunders; 1993:166–171.
7. Wallach J, Boever W. In: *Diseases of Exotic Animals, Medical and Surgical Management*. Saunders; 1983: 902–947.
8. Lowenstein L. Nutritional disorders of birds. In: Fowler ME, ed. *Zoo and Wildlife Medicine*, vol 2. WB Saunders; 1986:202–212.
9. Ward FP. Parasites and their treatment in birds of prey. In: Fowler ME, ed. *Zoo and Wild Animal Medicine*, vol 2. Philadelphia, PA: Saunders; 1986:425–430.
10. Giddings RF. Treatment of flukes in a toucan. *J Am Vet Med Assoc*. 1988;193:155–156.
11. Wagner RA. Acanthocephalid infections in the Sturnidae family. *Proc Am Assoc Zoo Vet*. 1982:51–53.
12. Mandani SA, Dorrestein GM. Filarial tenosynovitis caused by *Pelecitus* species (Spirurida, Filarioidea, Onchocercidae) in the legs of a channel-billed toucan (*Ramphastos vitellinus*). *J Avian Med Surg*. 2012;26: 36–39.
13. Dubey JP, Lane E, Van Wilpe E. *Sarcocystis ramphastosi* sp. nov and *Sarcocystis sulfuratusi* sp. nov. (Apicomplexa, Sarcocystidae) from the keel-billed toucan (*Ramphastos sulfuratus*). *Acta Parasitologica*, 2004;49:93–101.
14. Visvesara GS, Booton GC, Kelley DJ, et al. In vitro culture, serologic, and molecular analysis of *Acanthamoeba* isolated from the liver of a keel-billed toucan (*Ramphastos sulfuratus*). *Vet Parasit*. 2007;143:74–78.
15. Van Zeeland YRA, Schoemaker JN, Kik MJL, et al. Upper respiratory tract infection caused by *Cryptosporidium baileyi* in three mixed-bred falcons (*Falco rusticolus* x *Falco cherrug*). *Avian Dis*. 2008;52:357–363.
16. Mikich SB, Jennings J, Cubas ZS. Order Piciformes (toucans, woodpeckers). In Fowler ME, Cubas ZS, eds. *Biology, Medicine, and Surgery of South American Wild Animals*. Ames, IA: Iowa State University Press; 2001: 180–199.
17. Charlton BR, Barr BC, Castro AE, et al. Herpes viral hepatitis in a toucan. *Avian Dis*. 1990;34:787–790.
18. Worrell AB. Toucans and mynahs. In: Altman N, Clubb S, Dorrestein J, et al, eds. *Avian Medicine and Surgery*. Philadelphia, PA: Saunders; 1997:910–918.
19. Forbes NA, Altman RB. *Self-Assessment Color Review of Avian Medicine*. London: Manson Publishing; 1998: 10–12.
20. Rodrigues de Oliveira L, Oliveira dos Santos D, de Paula Martins Pereira M, et al. A retrospective study of hepatic hemosiderosis and iron storage disease in several captive and free-ranging avian species. *J Zoo Wild Med*. 2022;53:455–460.
21. Lowenstein L, Munson L. Iron overload in the animal kingdom. In: Fowler M, Miller RE, eds. *Zoo and Wildlife Medicine*, vol 4. Philadelphia, PA: Saunders; 1999: 260–268.
22. Lowenstein L, Petrak ML. Iron pigments in the livers of birds. In: Montali RJ, Migaki G, eds. *Comparative Pathology of Zoo Animals*. Washington DC: Smithsonian Institution Press; 1980:127–235.
23. Hochleitner M, Hochleitner C, Harrison LD. Evaluating the liver. In: Harrison G, Lightfoot T, eds. *Clinical Avian Medicine*. Redondo Beach, FL: Spix Publishing; 2006: 445–446.
24. Seibels R, Lamberski N, Gregory C, et al. Effective use of tea to limit dietary iron available to starlings (*Sturnus vulgaris*). *J Zoo Wild Med*. 2003;34:314–316.
25. Wilson RB. Hepatic hemosiderosis and *Klebsiella* bacteremia in a green aracari (*Pteroglossus viridis*). *Avian Dis*. 1994;38:679–681.
26. Schmidt RE, Reavill D, Phalen DN. *Pathology of Pet and Aviary Birds*. Ames, IA: Iowa State University Press; 2003:8.
27. Wobeser GA. *Diseases of Wild Waterfowl*. New York, NY: Plenum Press; 1981:213–214.
28. Brayton C. Amyloidosis, hemochromatosis, and atherosclerosis in a roseate flamingo. (*Phoenicopterus ruber*). *Ann NY Acad Sci*. 1992;653:184–190.
29. MacWhirter P. Passeriformes. In: Ritchie BW, Harrison G, Harrison LR, eds. *Avian Medicine: Principles and Application*. Brentwood, TN: HBD Inc; 1999:1173–1179.
30. Nakamura K, Tanaka H, Kodama Y, et al. Systemic amyloid in laying Japanese quail. *Avian Dis*. 1998; 42:209–214.
31. St. Leger J. Avian atherosclerosis. In: Fowler ME, Miller RE, eds. *Zoo and Wildlife Medicine, Current Therapy 6*. Philadelphia, PA: Saunders; 2008:200–205.
32. Evans A, Atikns A, Citino S. Tracheal stenosis in a blue-billed currawong (*Crax alberti*). *J Zoo Wildl Med*. 2009;49:373–377.
33. Miller M, Weber M, Mangold B, et al. Tracheal resection and anastomosis in storks. *Proc Am Assoc Zoo Vets*. 2001: 201–205.
34. Sykes J, Neiffer D, Terrell S, et al. Review of postintubation tracheal obstruction in birds. *J Zoo Wild Med*. 2013;44:700–713.
35. Mainez M, Cardona T, Juan-Salles C, et al. Bilateral renal tubular neoplasm in a channel-billed toucan (*Ramphastos vitellinus*). *J Avian Med Surg*. 2015;29:46–50.